

Original Article

# The long time follow-up of craniovertebral junction fixation in patients with rheumatoid arthritis

Kadir Kotil

Department of Neurosurgery, TC Istanbul Arel University Tepekent, Istanbul, Turkey

Corresponding author: Prof. Kadir Kotil, Hasan Ali Yücel Sok. Senil Apt. 36/14, Çiftehavuzlar Kadikoy, Istanbul, Turkey 34728. E-mail: [kadirkotil@gmail.com](mailto:kadirkotil@gmail.com)

Journal of Craniovertebral Junction and Spine 2012, 3:11

## Abstract

**Background:** Rheumatoid arthritis (RA) can have very destructive effects, especially in the cervical spine. Bone quality is poor in these patients. The purpose of this study is to evaluate the feasibility of fusion and accuracy of fluoroscopy in cervical transpedicular fixation (CPF) in a standardized clinical protocol for RA patients. **Materials and Methods:** 96 pedicles of 15 patients operated between January 2000 and May 2010 due to atlanto-axial and subaxial cervical subluxation were investigated for post-operative malposition of the transpedicular screws. Three-dimensional computed tomography was used as a useful tool in preoperative planning and in transarticular or transpedicular screw placement with the free hand technique in the cervical spine of RA patients. Fixation and reduction with fusion was performed in all of the patients, and autografts from iliac wing were used for fusion. Ranawat's and Nurick scales were used to assess the results. All screws were evaluated by Kast's criteria. Fusion or stability was evaluated on plain radiographs taken 3 weeks and 6, 12 and 60 months after the surgery. **Results:** Female to male ratio was 6/9. The mean age at the time of surgery was 57.4 years (range 44-72 years). Five of the patients were operated for both C1-2 and subaxial subluxation. Two of the 15 patients had only C1-2 subluxation and the remaining eight patients had only subaxial cervical subluxation. The screws were at their correct places in 84 pedicles (87.5%) while minor breach was detected in 9 (10.9%). According to Ranawat's criteria, seven patients remained the same, and eight patients showed improvement. Instrumentation failure, loss of reduction or non-union was not observed at the final follow-up (average 31.5 months; range 24-60 months). **Conclusion:** CPF provides a very strong three column stabilization and solid fusion in the osteoporotic vertebrae, but also carries a risk of vascular injury without nerve damage or in the RA patients, but the risk is low in experienced hands.

**Key words:** Cervical pedicle, cervical posterior fixation, craniovertebral junction, follow-up, rheumatoid arthritis

## INTRODUCTION

There are various cervical disorders caused by rheumatoid arthritis (RA). Clinical as well as radiological signs of rheumatoid changes of the cervical spine are present in up

to 86% of all RA patients. The cervical spine is the second most frequently affected anatomic region in RA.<sup>[1]</sup> The most common type of anatomical cervical spine deformity is anterior atlanto-axial subluxation (AAS), followed by subaxial and vertical subluxation.<sup>[2,3]</sup> These conditions may cause myelopathy, severe pain, or both; any of which may impair the quality of life of RA patients.<sup>[4]</sup> Innovative methods such as C1/2 transarticular and cervical pedicle screw techniques provide greater biomechanical stability compared to conventional posterior fusion techniques.<sup>[5,6]</sup> A number of internal fixation procedures have been used for instability of the cervical spine. Lateral mass screws have been used for a long time whereas pedicle screws have started to be used more recently. There is superior biomechanical stability with cervical transpedicular

Access this article online	
Quick Response Code:	Website: <a href="http://www.jcvjs.com">www.jcvjs.com</a>
	DOI: 10.4103/0974-8237.116532

fixation (CPF) compared to the use of lateral mass screws, and wiring techniques.<sup>[7,8]</sup> Jones, Kast and Nolte *et al.*<sup>[9,10,11]</sup> reported that cervical pedicle screws have a significantly higher resistance to pull-out forces than lateral mass screws. The purpose of this study is to evaluate the feasibility of fusion and accuracy of fluoroscopy in CPF in a standardized clinical protocol for RA patients.

## MATERIALS AND METHODS

Between January 2000 and May 2010, a total of 15 patients (9 male, 6 females) with cervical disorders due to RA were surgically treated using intraoperative fluoroscopy. Ranawat's criteria were used to assess the patients.<sup>[4]</sup> The presence of AAS and/or subaxial subluxation (SAS) as well as vertical migration of the odontoid was recorded and quantified. In addition, the anterior atlantodental interval was assessed both pre- and post-operatively. All radiologic measurements performed by a radiologist (Y. S). We established a surgical plan a day before surgery and confirmed the insertion point of screws, applicability of screws, pedicle investigation, and screw position in relation to vertebral artery (VA).

The patients were evaluated for both Magerl's technique and CPF technique. Coronal three-dimensional computed tomography (CT) was performed for every patient for the evaluation the surgical plan in the pre-operative period. Then, the entrance holes, direction, diameter, and depth of the screws were depicted with a cursor on the pedicle anatomy, and the surgery was initiated. In the prone position, after exposure of the posterior bony elements of the spine, the screws were inserted under fluoroscopy guidance using the free-hand technique. Kast's criteria were used to assess the positions of the pedicle screws.

Ranawat's classification is defined as follows:

- Class 1: No neural deficit;
- Class 2: Subjective weakness with hyper-reflexia and dysesthesia;
- Class 3A: Objective findings of paresis and long-tract signs, but ambulation possible;
- Class 3B: Quadriparesis with resultant inability to walk or to feed oneself. Occipital or cervical pain was classified into four grades according to Ranawat's criteria:<sup>[4]</sup>

- Grade 0: None;
- Grade 1: Mild, intermittent, requiring only aspirin analgesia;
- Grade 2: Moderate, cervical collar required;
- Grade 3: Severe, pain not relieved by either aspirin or collar.

### Grading of the pedicle screw position (Kast's criteria)

- Grade I: Screw centered in the pedicle causing only minor plastic deformation of the pedicle cortex at most.
- Grade IIA: Screw threads or less than one-fourth of the screw cross section penetrating the cortex; no contact of the screw with the spinal cord, nerve root or VA.
- Grade IIB: More than one-fourth of the screw cross section penetrating the cortex but no contact with neurovascular

Kotil: In craniovertebral junction and rheumatoid arthritis

structures.

Grade III: Screw position according to grade II, however, in contact with neurovascular structures.

In all patients, autogenous iliac bone grafts were used. Patients were permitted to stand and walk from the day after the operation without a collar, since CPF provided enough stability to ambulate without it. Radiological assessment of screw placement was performed. All patients underwent reconstructed CT scans along with plain AP, lateral, and oblique X-ray films of instrumented levels after surgery. Clinical results were based on evaluations of the patients' follow-up data. The surgeon performed the follow-up investigation and radiographic assessment.

## RESULTS

The mean age at the time of surgery was 57.4 years (range 44-72 years). 2 (1.3%) of the 15 patients had AAS, 5 (33.3%) had AAS and vertical subluxation (VS) of the cervical spine, 8 (53.3%) had SAS. According to Ranawat's classification,<sup>[12]</sup> the neurological deficit was class 3 in six cases (class 3A in three, class 3B in three). C1/2 transarticular screw fixation was performed in 7 (46.6%) patients, only mid and lower cervical fusion was performed using transpedicular screws in 8 (53.3%) patients, combined fusion (C1-2 + subaxial) procedure in five patients (33.3%). Pre-operative pain assessments were grade 1 in one case, grade 2 in six cases and grade 3 in eight cases. In 10 of the 15 cases (66.6%), occipital or neck pain as classified by Ranawat's criteria for pain had improved post-operatively [Table 1]. A total of 96 screws, including 14 C1/2 transarticular screws and 82 transpedicular screws were inserted using fluoroscopy. Based on Kast's criteria, 14 transarticular screws and 79 transpedicular screws were correctly placed. No neurovascular compression of the C2 level was present. Screws were either completely within cortical walls of the pedicle or with a maximal cortical perforation of 1 mm as seen on CT. This group comprised 84 (87.5%) of the implanted screws, including both transarticular and transpedicular screws.

Lateral or ventral perforation of the vertebral body occurred in two screws (C4, C6), slight impact to the lateral recess without dural contact occurred in three screws (C3, C4, C5) and narrowing of the vertebral canal less than 25% of its diameter was observed in two screws (grade IIA and less; C3, C4). In summary, seven screws (7.25% of all screws) showed minor breach (grade 1 and II) radiologically.

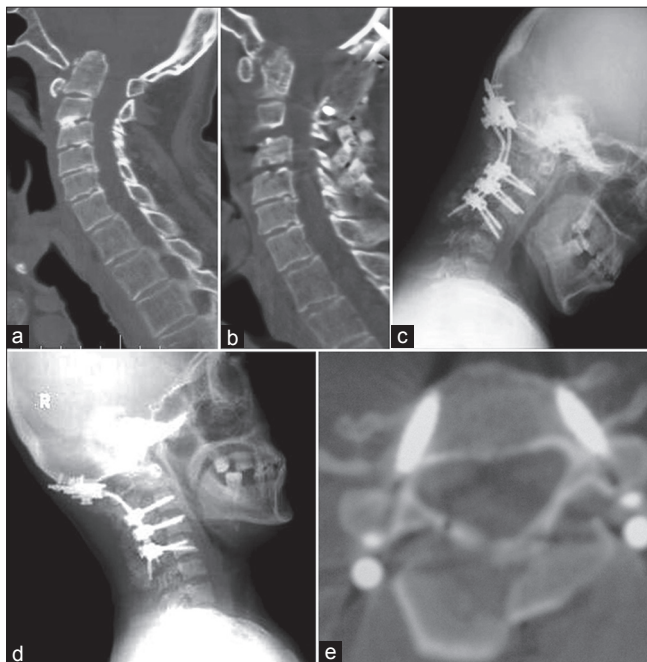
Average operative time was 122 min (range 95-205 min) and the average intraoperative blood loss was 280 ml (range 50-330 ml).

According to Ranawat's classification, 7 of 15 patients remained the same (46.6%) and eight patients showed improvement [Table 1]. In 10 of the 15 cases (66.6%), occipital or neck pain as classified by Ranawat's criteria for pain had improved.

No instrumentation failure, loss of reduction or nonunion is observed at the final follow-up period (average 49.5 months; range 24-60 months). One characteristic case is presented in

**Table 1: Epidemiological data of enrolled patients (n=15), according to pre-operative Ranawat score and malposition grading**

Case no	Age/ sex	cervical level	Ranawat c. preop-postop		Pain preop-postop		malposition grade
1	56/M	C1-2	2	2	2	1	1
2	44/M	C1-2	3A	3A	3	2	1
3	66/M	C1-2+C3-4	3B	2	3	2	1
4	72/F	C4-5	2	2	2	2	1
5	67/M	C4-5	2	1	2	1	3
6	58/F	C1-2+C4-5	3A	3A	3	1	0
7	71/M	C4-5	2	1	3	2	0
8	44/M	C3-4	2	1	2	1	3
9	59/F	C2-3	3B	3B	3	1	0
10	51/M	C1-2+C3-4	2	2	2	2	0
11	49/F	C4-5	3A	1	3	1	3
12	65/F	C3-4	2	1	2	2	0
13	44/M	C1-2+C4-5	2	2	1	1	1
14	55/F	C1-2+C3-4	3B	3A	3	3	0
15	61/M	C3-4	2	1	3	2	1



**Figure 1:** This is a 56-year-old patient with rheumatoid arthritis who presented with subaxial pain and myelopathy. Computed tomography sagittal reconstructions show (a) atlanto-axial dislocation (b) decompression of the craniovertebral junction in the midline and instrumentation and fusion from the occiput to the midcervical spine. No any instability was demonstrated by dynamic flexion (1c) and extension X-rays (1d) after the postoperatuar period (15 mo). Fusion was demonstrated by CT [Figure 1e]

Kotil: In craniovertebral junction and rheumatoid arthritis

Figure 1. Furthermore, instability was checked by dynamic X-rays in the follow-up period. Bony fusion was defined as an absence of segmental motion in functional lateral X-rays with the presence of solid bony union observed in reconstruction CT.

## DISCUSSION

In patients suffering from RA, involvement of all cervical spine is a common entity that necessitates the concern of both the rheumatologist and the spine surgeon for a proper therapeutic regimen. RA can result in serious damage to the cervical spine and the neuraxis, ranging from mild instability to myelopathy and death.<sup>[12]</sup> The ideal surgical approach should allow easy access to multiple levels and provide various osseous points of fixation. When surgical intervention is anticipated, it should be performed before the development of severe myelopathy. Patients who progress to a Ranawat III-B status have a much higher morbidity and mortality rate associated with surgical intervention than patients who are ambulatory.<sup>[13,14]</sup> In contrast, the current study shows the potential importance of surgery for class 3 patients, which provided excellent clinical results. CPF and C1/2 transarticular screw fixation are biomechanically superior to other conventional procedures using wiring or clamping.<sup>[5-7,15]</sup> Furthermore, CPF is a useful technique because laminectomy or laminoplasty can be performed simultaneously.

Conventional screw insertion techniques for both C1/2 screw and pedicle screw placement in the subaxial cervical spine rely on anatomical landmarks and intraoperative fluoroscopy. However, in RA patients, several specific illness-related problems of the cervical spine make surgical treatment extremely difficult. The use of corticosteroid medication for several years and immobilization of the spine caused by multiple musculoskeletal deformities, and dysfunctions lead to considerable osteoporosis. Occipital bone is nearly in nuchal region and provides excellent fixation. Thus, especially in RA patients, fixations are performed at the occipitocervical region using iliac crest autografts. Occipitocervical construction must be strengthened in the osteoporotic cervical spine by transpedicular screw fixation.<sup>[16]</sup>

Especially, when the VA runs an abnormal course, screw placement has a potential risk of neurovascular injury, and VA injury on the dominant side can cause cerebellar infarction and possibly fatal sequelae.<sup>[8,17,18]</sup> Moreover, due to severe spinal deformity and small anatomical size of the vertebrae (the lateral mass and pedicle) in the most RA cervical lesions, screw placement procedures are highly technically demanding and pose the potential risk of neurovascular injury even when intraoperative fluoroscopy is used. Pre-operative VA evaluation by CT angiography revealed unilateral stenosis or occlusion in 20% of patients (3 patients), all of whom weren't complicated with VS.<sup>[19]</sup> Abnormality of VA is highly likely in RA patients because of the cervical deformity. Tumialan *et al.*<sup>[19]</sup> reported cerebral and cerebellar infarction in rheumatoid cervical spine patients caused by VA injury, observed during anterior corpectomy. Taking that report in consideration, when pedicle diameter was narrow, non-dominant side was approached first to



avoid VA occlusion or stenosis and concurrent stroke.

The current study clearly shows with the clinical results that free-hand screw insertion in the rheumatoid cervical spine enables a significant reduction in the screw malplacement rates (3/96; 2.1%). Börm *et al.*<sup>[20]</sup> reported transarticular C1–C2 screw fixation performed in 14 cases using computer navigation (STN 4.0; Zeiss Company, Oberkochen Germany). In this study, there was one medial perforation of a C2 pedicle wall and one malposition of the screw in C2 without reaching the lateral mass of C1 (2/28; 7.1%). In contrast, there were no malpositions of the transarticular screws among our cases.

Due to the fragile bone quality of the RA cervical spine, care must be taken during rod or plate application procedures and reduction maneuvers which may cause cut-out and displacement of the screw from its original position. To prevent these injuries, preoperative evaluation of the vertebral artery and planning of screw insertion are indispensable. In general, insertion of screws into the pedicle of less than 3.5 mm in diameter should be avoided even with navigation assistance<sup>[21,22]</sup> This study showed that 3.5 and 4 mm pedicle screws might be suitable for transpedicular screw placement in the Turkish population.

In our opinion, conventional methods of inserting pedicle screws are still important for a safe and current procedure, despite the use of a computer navigation system. In addition, some other authors have also reported techniques of pedicle screw placement.<sup>[21,22]</sup> However, currently, the authors think that only surgeons experienced in transpedicular screw fixation and surgery of the cervical spine should perform this method of instrumentation.

Takahashi *et al.* reported a total of 21 patients with cervical disorders due to RA were surgically treated using the image-guidance system. Post-operative CT and plane X-ray was used to determine the accuracy of the screw placement. Neural and vascular complications associated with screw insertion and post-operative neural recoveries were evaluated. Post-operative radiological evaluations revealed that only 1 (2.1%; C4) of 48 screws inserted into the cervical pedicle had perforated the VA canal more than 25% (critical breach). However, no neurovascular complications were observed. According to Ranawat's classification, nine patients remained the same, and 12 patients showed improvement. Instrumentation failure, loss of reduction or nonunion was not observed at the final follow-up. In their study, the authors demonstrated that image-guidance systems could be applied safely to the cervical lesions caused by RA. Image-guidance systems are useful tools in pre-operative planning and in transarticular or transpedicular screw placement in the cervical spine of RA patients.<sup>[23]</sup>

Goel *et al.* had described a technique of interarticular plate and screw method of atlantoaxial fixation in the year 1988 and had recently discussed distraction and realignment of the atlantoaxial joint for basilar invagination and fixed atlantoaxial dislocation for cases with congenital

malformations of the region and for RA.<sup>[24,25,26,27,28]</sup> They observed that the distraction and impaction of the titanium spacer within the joint cavity increased the height of the lateral masses, reduced the basilar invagination and restored the craniovertebral alignments. As no wire, screws, plates, and rods were used for fixation as is conventionally the norm; the extent of stability provided by the implant will have to be assessed by a larger experience over a longer period of time. Following surgery both the patients showed symptomatic improvement and partial restoration of craniovertebral alignments.

Goel *et al.* reported one patient who had rheumatoid arthritis with pannus formation; the patient underwent lateral mass reconstruction with distraction of the facets and impaction of a spiked metal spacer and bone graft within the joint. Investigations done in the immediate postoperative phase showed complete disappearance of retroodontoid pannus in addition to reduction of basilar invagination and atlantoaxial dislocation.<sup>[26]</sup> These techniques seem very effective procedures for the pannus formation, but these new techniques and we have not experience.

The accuracy of a free-hand technique for correct pedicle screw fixation of the cervical spine has been not confirmed by laboratory tests. Although the current study does not include a large number of patients, the results of surgery under the fluoroscopy system are encouraging. Use of this system in cervical instrumentation surgery for RA patients can aid in reducing the risk of screw misplacement.

## CONCLUSION

The authors want to emphasize that that free-hand technique could be applied safely to the cervical lesions caused by RA. However, the risk of screw related perforation does not vanish completely.

## REFERENCES

1. Lipson SJ. Rheumatoid arthritis of the cervical spine. *Clin Orthop Relat Res* 1984;182:143-9.
2. Clark CR. Rheumatoid involvement of the cervical spine. An overview. *Spine (Phila Pa 1976)* 1994;19:2257-8.
3. Sharp J, Purser DW, Lawrence JS. Rheumatoid arthritis of the cervical spine in the adult. *Ann Rheum Dis* 1958;17:303-13.
4. Ranawat CS, O'Leary P, Pellicci P, Tsairis P, Marchisello P, Dorr L. Cervical spine fusion in rheumatoid arthritis. *J Bone Joint Surg Am* 1979;61:1003-10.
5. Grob D, Crisco JJ 3<sup>rd</sup>, Panjabi MM, Wang P, Dvorak J. Biomechanical evaluation of four different posterior atlantoaxial fixation techniques. *Spine (Phila Pa 1976)* 1992;17:480-90.
6. Kotani Y, Cunningham BW, Abumi K, McAfee PC. Biomechanical analysis of cervical stabilization systems. An assessment of transpedicular screw fixation in the cervical spine. *Spine (Phila Pa 1976)* 1994;19:2529-39.
7. Abumi K, Kaneda K, Shono Y, Fujiya M. One-stage posterior decompression and reconstruction of the cervical spine by using pedicle screw fixation systems. *J Neurosurg* 1999;90:19-26.
8. Abumi K, Shono Y, Ito M, Taneichi H, Kotani Y, Kaneda K. Complications of pedicle screw fixation in reconstructive surgery of the cervical spine. *Spine (Phila Pa 1976)* 2000;25:962-9.
9. Jones EL, Heller JG, Silcox DH, Hutton WC. Cervical pedicle screws versus lateral mass screws. Anatomic feasibility and biomechanical comparison.

- Spine (Phila Pa 1976) 1997;22:977-82.
10. Kast E, Mohr K, Richter HP, Börm W. Complications of transpedicular screw fixation in the cervical spine. *Eur Spine J* 2006;15:327-34.
  11. Nolte LP, Zamorano LJ, Jiang Z, Wang Q, Langlotz F, Berlemann U. Image-guided insertion of transpedicular screws. A laboratory set-up. *Spine (Phila Pa 1976)* 1995;20:497-500.
  12. Santavirta S, Konttinen YT, Laasonen E, Honkanen V, Antti-Poika I, Kauppi M. Ten-year results of operations for rheumatoid cervical spine disorders. *J Bone Joint Surg Br* 1991;73:116-20.
  13. Casey AT, Crockard HA, Bland JM, Stevens J, Moskovich R, Ransford AO. Surgery on the rheumatoid cervical spine for the non-ambulant myelopathic patient-too much, too late? *Lancet* 1996;347:1004-7.
  14. Sunahara N, Matsunaga S, Mori T, Ijiri K, Sakou T. Clinical course of conservatively managed rheumatoid arthritis patients with myelopathy. *Spine (Phila Pa 1976)* 1997;22:2603-7.
  15. Magerl F, Seemann PS. Stable posterior fusion of the atlas and axis by transarticular screw fixation. In: Kehr P, Weidner A, editors. *Cervical Spine I*. Berlin, Heidelberg, New York: Springer; 1987. p. 322-7.
  16. O'Brien MF, Sutterlin III CE. Occipitocervical biomechanics: Clinical and biomechanical implications for posterior occipitocervical stabilization and fusion. *Spine* 1996;10:281-313.
  17. Shintani A, Zervas NT. Consequence of ligation of the vertebral artery. *J Neurosurg* 1972;36:447-50.
  18. Smith MD, Emery SE, Dudley A, Murray KJ, Leventhal M. Vertebral artery injury during anterior decompression of the cervical spine. A retrospective review of ten patients. *J Bone Joint Surg Br* 1993;75:410-5.
  19. Tumialan LM, Wippold FJ 2<sup>nd</sup>, Morgan RA. Tortuous vertebral artery injury complicating anterior cervical spinal fusion in a symptomatic rheumatoid cervical spine. *Spine (Phila Pa 1976)* 2004;29:E343-8.
  20. Börm W, König RW, Albrecht A, Richter HP, Kast E. Percutaneous transarticular atlantoaxial screw fixation using a cannulated screw system and image guidance. *Minim Invasive Neurosurg* 2004;47:111-4.
  21. Kim HS, Heller JG, Hudgins PA, Fountain JA. The accuracy of computed tomography in assessing cervical pedicle screw placement. *Spine (Phila Pa 1976)* 2003;28:2441-6.
  22. Liu YJ, Tian W, Liu B, Li Q, Hu L, Li ZY, et al. Comparison of the clinical accuracy of cervical (C2-C7) pedicle screw insertion assisted by fluoroscopy, computed tomography-based navigation, and intraoperative three-dimensional C-arm navigation. *Chin Med J (Engl)* 2010;123:2995-8.
  23. Takahashi J, Shono Y, Nakamura I, Hirabayashi H, Kamimura M, Ebara S, et al. Computer-assisted screw insertion for cervical disorders in rheumatoid arthritis. *Eur Spine J* 2007;16:485-94.
  24. Goel A, Sharma P. Craniovertebral realignment for basilar invagination and atlantoaxial dislocation secondary to rheumatoid arthritis. *Neurol India* 2004;52:338-41.
  25. Goel A, Pareikh S, Sharma P. Atlantoaxial joint distraction for treatment of basilar invagination secondary to rheumatoid arthritis. *Neurol India* 2005;53:238-40.
  26. Goel A, Dange N. Immediate postoperative regression of retroodontoid pannus after lateral mass reconstruction in a patient with rheumatoid disease of the craniovertebral junction. Case report. *J Neurosurg Spine* 2008;9:273-6.
  27. Goel A, Laheri VK. Plate and screw fixation for atlanto-axial dislocation. (Technical report). *Acta Neurochir (Wien)* (1994) 129:47-53.
  28. 28. Goel A, Desai K, Muzumdar D. Atlantoaxial fixation using plate and screw method: A report of 160 treated patients. *Neurosurgery* 51; 1351-1357, 2002.

**How to cite this article:** Kotil K. The long time follow-up of craniovertebral junction fixation in patients with rheumatoid arthritis. *J Craniovert Jun Spine* 2012;3:42-6.  
**Source of Support:** Nil, **Conflict of Interest:** None declared.

Copyright of Journal of Craniovertebral Junction & Spine is the property of Medknow Publications & Media Pvt. Ltd. and its content may not be copied or emailed to multiple sites or posted to a listserv without the copyright holder's express written permission. However, users may print, download, or email articles for individual use.